

Dementia With Lewy Bodies: A Review Of Clinical Diagnosis, Neuropathology And Management Options

Tanis J. Ferman, Ph.D.

The Lewy body was identified as the neuropathologic hallmark of Parkinson's disease in 1912. In 1961, Okazaki¹ first described a relationship between the presence of cortical Lewy bodies and dementia, later confirmed by others.^{2,3} Based on several autopsy series, Dementia with Lewy bodies (DLB) is now considered to be the second most common form of dementia, accounting for about 20% of dementia, following Alzheimer's disease (AD) which accounts for about 60%.² DLB tends to affect males more than females and the age of onset typically falls between age 50 and 80, with a duration of illness of about 6 years.⁴ It is considered to have a more rapid progression than pure AD⁵ however in some patients the initiation of neuroleptic medication may be associated with increased morbidity and mortality.⁶ Coronal MRI images reveal significantly greater medial temporal (hippocampal) atrophy in AD than in DLB or vascular dementia, a relationship that is related to severity of memory impairment.⁷ Early detection and differentiation of DLB from other conditions is important for determination of treatment options and to provide caregivers and patients with information and resources to help behaviorally manage behaviors associated with DLB.

Clinical Diagnosis

In 1996, consensus criteria were put forth that identify 3 core features for the clinical diagnosis of DLB: fluctuating alertness/cognition, recurrent fully formed visual hallucinations and spontaneous parkinsonism⁸ (see Table 1). De-

Table 1. Core And Supportive Features For The Clinical Diagnosis Of DLB.¹³

1. The central feature required for a diagnosis of DLB is progressive cognitive decline of sufficient magnitude to interfere with normal social or occupational function.
2. Two of the following core features are essential for a diagnosis of probable DLB, and one is essential for possible DLB.
 - a. Fluctuating cognition with pronounced variations in attention and alertness
 - b. Recurrent visual hallucinations that are typically well formed and detailed.
 - c. Spontaneous motor features of parkinsonism.
3. Features supportive of the diagnosis are
 - a. repeated falls
 - b. syncope
 - c. transient loss of consciousness
 - d. neuroleptic sensitivity
 - e. systematized delusions
 - f. hallucinations in other modalities.

mentia plus two clinical features are needed for a diagnosis of probable DLB, and one for a diagnosis of possible DLB. Cognitive impairment typically precedes or coincides with the onset of the clinical features.⁹ Studies addressing sensitivity (proportion of cases positively identified) and specificity (proportion of negative cases correctly identified) with other neurodegenerative conditions using neuropathology have reasonably good specificity rates of about 0.80, but variable sensitivity rates.¹⁰⁻¹² This variability is at least partly attributable to mixed agreement regarding what constitutes fluctuations and difficulty differentiating between DLB and AD late in disease course. When the analysis is confined to patients with dementia ranging from mild to moderate dementia, sensitivity ratings of DLB improve.¹¹ Further work is needed to identify whether the presence of other co-existent disorders serves to improve the diagnostic accuracy of DLB. REM sleep behavior disorder (RBD) occurs with a greater frequency in DLB relative to AD and may be a useful clinical indicator of DLB.

What Is The Dementia In LBD Like?

Dementia in the form of progressive cognitive deterioration and impaired functional ability must be present for a diagnosis of DLB to be made. Early in the disease course, there are differences in the patterns of cognitive impairment for DLB and AD. However, as with any degenerative dementia, later stages of the illness result in prominent generalized cognitive impairment that makes differential diagnosis difficult or impossible.

Initial cognitive complaints in DLB frequently include problems with short or variable attention span and visual perceptual difficulties, and does not always involve a primary memory complaint. Severe visual constructional and perceptual-organizational deficits are commonly observed in DLB.¹³⁻¹⁵ These higher order visual difficulties in DLB are not associated with the presence or absence of parkinsonism¹³ but are worse in patients with visual hallucinations.¹⁵ Clinically diagnosed patients with DLB perform significantly worse on tasks of visual perceptual organization, attention and speeded word generation (letter fluency) than patients of similar dementia severity with autopsy confirmed AD. In contrast, the AD group showed significantly worse performance on confrontation naming and

Tanis J. Ferman, Ph.D. is with the Department of Psychiatry and Psychology at Mayo Clinic Jacksonville.

This paper is funded in part by grant NIA AG15866.

verbal memory when compared to the DLB group.⁹ The disproportionate relationship between higher order visual processing and memory may be helpful in differentiating DLB from AD early in disease course.

Noncognitive Clinical Features Of Dementia With Lewy Bodies

Parkinsonism

Bradykinesia, rigidity and gait disturbance are the most common parkinsonian features in DLB, but resting tremor is relatively rare.⁴ Masked facies, stooped posture, hypophonic speech, and unexplained falls may also be present. In DLB, the extrapyramidal features should be spontaneous and not associated with striatal infarction or neuroleptic use.⁸ Consensus criteria indicates that the dementia and parkinsonian signs should occur within a year of each other in order to qualify for the diagnosis of DLB.⁸ This temporal designation appears to be an effort to clinically differentiate DLB from idiopathic PD and dementia on the continuum of Lewy body disease.

Compared to Parkinson's disease, extrapyramidal symptoms in DLB tend to be milder and more symmetric at presentation.¹⁷ Clinical parkinsonism is present in 67% of our sample of 84 patients with clinically diagnosed DLB, a frequency of occurrence similar to what has been reported in other samples.¹⁸ Patients without parkinsonism during life may still have Lewy body disease and Lewy body pathology in the substantia nigra.^{3,13} Hence, Lewy body pathology may be present in the brain, but the degree of neuronal loss in the substantia nigra may not reach the critical threshold needed to produce extrapyramidal signs.

Fluctuations

The fluctuations in DLB are described as variations in cognition or arousal that may range from lucid interaction to reduced clarity of awareness and clouded consciousness. Fluctuating arousal may reflect periods of unresponsiveness while awake (e.g., blanking out, zoning out), episodes of excessive somnolence despite adequate nighttime sleep, or periods of daytime behavioral confusion with limited awareness of surroundings alternating with normal or near normal function. Cognitive fluctuations have also been described as variability in the patient's cognitive or functional abilities and periods when the patient regains his or her ability to perform tasks that he or she was previously unable to carry out.^{8,10} Patients with AD or other forms of dementia may have subtle daily variations, and even though most families will describe the presence of good days and bad days, patients with AD typically do not show a pattern of losing and regaining abilities.

Some of the descriptions of fluctuations sound suspiciously similar to what is typically observed in delirium, and indeed, DLB fluctuations may look like a fluctuating delirium. Therefore, the importance of ruling out other

medical causes for delirium including medication side effects, recurrent low grade infections, uncontrolled or undiagnosed seizure disorder, unobserved head injury, or frequent TIAs is imperative. Further inquiry about triggers and patterns may be helpful in identifying alternate explanations for fluctuating cognition in dementia. Specifically, other non-neurologic contributors to fluctuations may include disrupted sleep/wake schedules, sleep disorders (e.g., obstructive sleep apnea syndrome), pain, emotional distress, restlessness, overstimulation and catastrophic reactions to tasks or situations that exceed the patient's cognitive capacity. Even when fluctuations are a feature in DLB, presence of one or more of the above factors will produce excess disability, that is, disability greater than that caused by the dementia alone.

Visual Hallucinations And Other Supportive Psychiatric Features

Visual hallucinations in DLB consist of fully formed, detailed, three dimensional objects, people or animals. These visual images must be recurrent and not a product of medication.⁸ Common examples of complex visual hallucinations include seeing people, lilliputions, animals or objects. Typically the visual images are of strangers, although it is not uncommon for the patient to see images of deceased or living friends or relatives. In our sample of 84 patients with clinically probable or possible DLB, 64% had recurrent visual hallucinations, a proportion that is consistent with other studies.¹⁹ Visual hallucinations that occur early rather than late in the disease course are better at discriminating between AD and DLB.¹⁹ In DLB the visual hallucinations often occur within the first year of cognitive impairment⁹ whereas the hallucinations in patients with vascular dementia or AD tend to occur an average of 6 years from the onset of the dementia.²⁰ Visual misperceptions (i.e., illusions) are also commonly observed in DLB and occur in 30% of this sample. Examples of object misperceptions in DLB include mistaking a hinge for a caterpillar, patterns on a rug for snakes, pillows as an animal or lamp as a person. In these situations, reducing clutter or replacing patterned material with non-patterned material may be helpful.

Delusional ideation is a supportive feature of DLB and appears to occur in a subgroup of those with visual hallucinations. There appear to be two predominant types of delusional ideation in DLB, visual misidentification delusions and false beliefs that appear congruent with the patient's visual hallucinations. Visual misidentification delusions, trouble recognizing one's spouse or home, are present in 13% of our sample. False ideas that are secondary to visual hallucination content occur in 24% of the sample. The most frequent delusional ideas include strangers or intruders in the home or the belief that deceased friends or family members are visiting.

Patients with auditory hallucinations (13% of sample) also have visual hallucinations. The auditory hallucinations are elementary and do not appear to include command or single voice hallucinations. Examples of elementary auditory hallucinations include banging, knocking, sizzling, a doorbell, footsteps, muffled voices, sounds of many people talking in a room or rummaging sounds.

Dream Enactment Behavior

Rapid eye movement (REM) sleep without muscle atonia may result in a release of motor activity during REM sleep that mirrors dream content. This clinical entity has been termed REM Sleep Behavior Disorder (RBD) and has been shown to co-occur with DLB, Parkinson's disease and Multiple System Atrophy^{21,22} but seems to rarely occur in AD or Frontal-Temporal dementia.²² Neuropathology of 3 cases with RBD and clinical features of DLB has confirmed the presence of diffuse Lewy body disease in these patients.¹³ In the Mayo series of patients with DLB and RBD, the average duration between RBD onset and estimated onset of cognitive decline is 9 years, with a range of 6 months to 53 years.⁹ At comparable levels of mild to moderate dementia, patients with RBD and dementia (but no clinical features of DLB) were cognitively indistinguishable from patients with DLB, but both groups differed from the AD group. These data provide evidence that RBD may be a heralding feature of DLB, and RBD in the context of dementia may represent DLB.

Neuropathology

The defining neuropathologic characteristics of DLB are Lewy bodies, Lewy neurites, and spongiform encephalopathy in the amygdala, entorhinal cortex and temporal gyrus.^{23,24} Lewy bodies are rounded intracytoplasmic neuronal inclusions and Lewy neurites are diffuse and filamentous inclusions (see Figure 1). Lewy bodies and Lewy neurites are largely comprised of alpha synuclein,²⁵ a protein normally expressed in neuronal synapses with a possible role in synaptic vesicle release. The mechanism causing the abnormal accumulation of alpha-synuclein in Lewy bodies and Lewy neurites is not yet known, but it is evident that some neuronal regions are more vulnerable to Lewy body formation than others. About a third of patients with DLB also have AD pathology. This is predominantly in the form of diffuse plaques without a neuritic core or tau positivity, and is similar to the diffuse plaques observed in nondemented elderly.^{26,27} Although neurofibrillary tangles are typically sparse or absent, when they are present they occur with accompanying neuritic plaques.²⁸ It is the degree of Lewy body burden and not the density of neuritic plaques or neurofibrillary tangles, that is related to DLB disease duration and severity of dementia.¹⁸

Choline acetyltransferase (ChAT), the enzyme that synthesizes acetylcholine shows significantly greater deple-

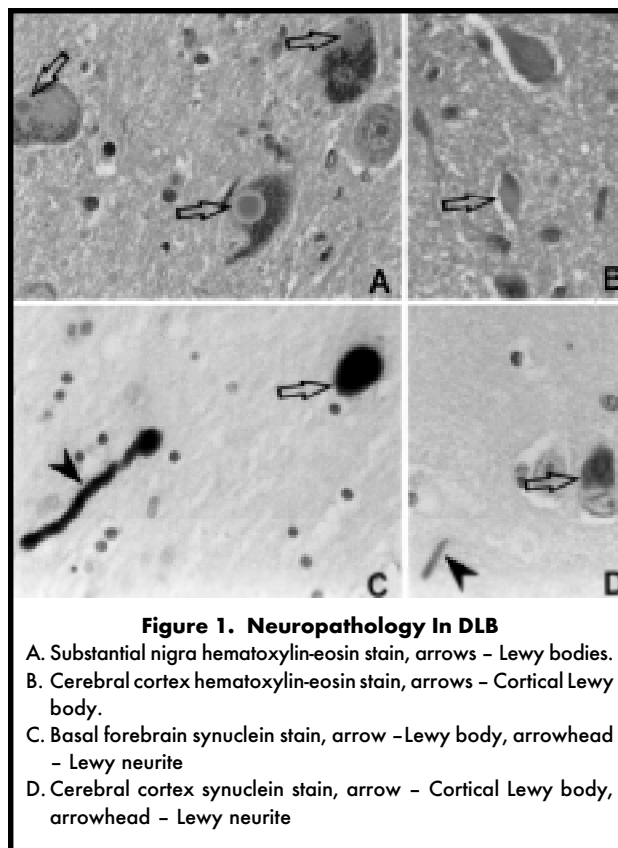


Figure 1. Neuropathology In DLB

- A. Substantia nigra hematoxylin-eosin stain, arrows - Lewy bodies.
- B. Cerebral cortex hematoxylin-eosin stain, arrows - Cortical Lewy body.
- C. Basal forebrain synuclein stain, arrow - Lewy body, arrowhead - Lewy neurite
- D. Cerebral cortex synuclein stain, arrow - Cortical Lewy body, arrowhead - Lewy neurite

tion in DLB compared to AD, and depletion is even more profound in DLB patients who are hallucinating.^{29,30} Perry and colleagues hypothesize that severe losses in basal forebrain acetylcholine could precipitate hallucinations and contribute to a delirium-like fluctuations in arousal. In support of this hypothesis, fluctuating cognition and consciousness are well known effects of anti-cholinergic drug toxicity.³¹ An alternate, but not necessarily mutually exclusive, hypothesis pertains to the involvement of brainstem neurons responsible for the initiation and maintenance of REM sleep and REM sleep atonia. In some instances, hallucinations may reflect an intrusion of dream sleep into waking state. The presence of RBD in patients with DLB provides evidence for the disruption of at least some of the mechanisms responsible for REM sleep.

Treatment And Management Issues In DLB

The goal of dementia treatment is to enable each individual to function at their best level of cognition, behavior and function. Other reversible causes of behavioral disturbances (i.e., infection, pain, hunger, medical causes) should always be considered. Neuroleptic medication, often a first line treatment of episodic confusion and hallucinations is frequently administered to patients with dementia. However, in patients with DLB, adverse reactions to neuroleptics have been documented and these reactions do not necessarily revert upon discontinuation of the medication.⁶ Neuro-

leptic sensitivity in DLB consists of a rapid decline with severely exaggerated extrapyramidal system, increased confusion and in 54% of one group of patients with DLB, it precipitated a terminal decline with death in 2 to 19 weeks of drug administration.⁶ This heightened sensitivity to neuroleptics in DLB appears to be caused by a failure to up-regulate striatal D2 receptors in response to dopaminergic antagonism.³³ Therefore, avoiding neuroleptics with a high affinity for D2 receptors when treating behavioral symptoms in DLB is prudent. Risperidone is no longer considered as useful as it was once thought because of significant D2 blocking properties,³⁴ documented side effects of parkinsonism,³⁵ and reports of neuroleptic sensitivity to risperidone in DLB.^{32,34} Clozapine has been shown to be effective in treating levo-dopa induced psychosis in Parkinson's disease.³⁶ However, clozapine and another atypical antipsychotic, olanzapine have significant anticholinergic properties that may worsen confusional state or cognitive function in AD or DLB.^{37,38} Quetiapine (Seroquel®) has both low cholinergic affinity and few D2 blocking properties, but no data is available on this usefulness of this drug in DLB.

Use of cholinesterase inhibitors in DLB has been examined in a series of small studies. Results indicate a reduction in the frequency and intensity of hallucinations, confusion and agitation in AD and DLB, and in some cases of DLB the results may be rather dramatic.³⁹⁻⁴² This benefit of cholinesterase inhibitors in DLB may be related to the depleted levels of choline acetyltransferase in DLB.²⁹ Research to date indicates that avoiding medications with anticholinergic properties and providing cholinergic replacement should be a primary consideration when treating the cognitive and behavioral symptoms of DLB. Benzodiazepines may negatively affect cognition and produce sedation, paradoxical agitation and increased risk of falls in the elderly. Stimulants are often used for the treatment of hypersomnolence in patients with narcolepsy or idiopathic hypersomnolence, but their use in treating the fluctuating arousal in DLB has not been investigated.

Nonpharmacologic interventions should always be included when managing behavior. Before treating the hallucinations or delusions, it must be determined whether these symptoms are actually harmful or distressing to the patient. Frequently these symptoms are more distressing to the family member than the patient, and in those situations providing the family with information regarding caregiving strategies may be most appropriate. Caregivers who learn what to expect as the disease progresses can anticipate the patient's limitations and the management of problem behaviors can be shifted from trying to change the patient to modifying other factors that may be causing or exacerbating the problem. Specifically, modifying the environment (e.g., increasing illumination, reducing clutter) and modi-

fying ways of responding to behavior (e.g., first by validating the patient's concern and then using redirection techniques) are examples of behavioral strategies that may serve to diminish patient and caregiver distress.⁴³ Utilizing available support services, including adult day programs, have also been shown to reduce caregiver-related stress and reported feelings of overload, strain, depression and anger.⁴⁴

Conclusions

A diagnosis of DLB requires the presence of dementia plus one of three core clinical features: fluctuations, parkinsonism and visual hallucinations. REM Sleep Behavior Disorder may also be an early feature in the disease course. Differential diagnosis from AD is quite difficult late in the disease course, but early differences between these two types of dementia may be seen in patterns of neurocognitive performance. Delusional ideation and elementary auditory hallucinations, when present, tend to occur in a subgroup of patients with visual hallucinations. Severely low levels of acetylcholine in the basal forebrain may account for some aspects of the fluctuating cognition and visual hallucinations in DLB and there is some evidence that cholinesterase inhibitors lead to some improvement of these symptoms. Neuroleptic sensitivity has been shown to occur in DLB due to reduced dopaminergic neurons and a failure to up-regulate D2 receptors in DLB. Nonpharmacologic interventions in the form of modifying responses to unusual behavior and reducing potential environmental and interactional triggers may also be helpful management suggestions for caregivers.

REFERENCES

1. Okasaki H, Lipkin LE, Aronson SM. Diffuse intracytoplasmic inclusions (Lewy type) associated with progressive dementia and quadriplegia in flexion. *J Neuropathol Exp Neurol.* 1961;20: 237-244.
2. Hansen L, Salmon D, Galasko D, et al. The Lewy body variant of Alzheimer's disease: A clinical and pathologic entity. *Neurology.* 1990; 40:1-8.
3. Dickson D, Davies P, Mayeux R, et al. Diffuse Lewy body disease: Neuropathological and biochemical studies of six patients. *Acta Neuropathologica.* 1987;75:8-15.
4. Cery SP, Bylsma FW. Lewy bodies and progressive dementia: a critical review and meta-analysis. *J of International Neuropsychological Society.* 1997; 3:179-194.
5. Olichney JM, Galasko D, Salmon DP, Hofstetter CR, Hansen LA, Katzman R, Thal LJ. Cognitive decline is faster in Lewy body variant than in Alzheimer's disease. *Neurology.* 1998; 51: 351-357.
6. McKeith I, Fairbairn A., Perry R, Thompson P, Perry E. Neuroleptic sensitivity in patients with senile dementia of the Lewy body type. *BMJ.* 1992; 305:673-8.
7. Barber R, Gholkar A, Scheltens P, Ballard C, McKeith IG, O'Brien JT. Medial temporal atrophy on MRI in dementia with Lewy bodies. *Neurology.* 1999; 52:1153-1158.
8. McKeith IG, Galasko D, Kosaka K, et al. Consensus guidelines for the clinical and pathologic diagnosis of dementia with Lewy bodies (DLB): Report of the consortium on DLB international workshop. *Neurology.* 1996; 47:1113-1124.

9. Ferman TJ, Boeve BF, Smith GE, Silber MH, Kokmen E, Petersen RC, Ivnik RJ. REM Sleep behavior disorder and dementia: Cognitive differences when compared with AD. *Neurology*. 1999;52:951-957.
10. Mega M, Masterman D, Benson DF, et al. Dementia with Lewy bodies: Reliability and validity of clinical and pathologic criteria. *Neurology*. 1996;47:1403-1409.
11. Verghese J, Crystal HA., Dickson DW, Lipton RB. Validity of clinical criteria for the diagnosis of dementia with Lewy bodies. *Neurology*. 1999; 53:1974-1981.
12. Lopez OL, Litvan I, Catt KE et al. Accuracy of four clinical diagnostic criteria for the diagnosis of degenerative dementias. *Neurology*. 1999; 53:1292-1299.
13. Boeve BF, Silber MH, Ferman TJ, et al. REM sleep behavior disorder and degenerative dementia: an association likely reflecting Lewy body disease. *Neurology*. 1998;51:363-370.
14. Connor DJ, Salmon DP, Sandy TJ, Galasko D, Hansen LA, Thal LJ. Cognitive profiles of autopsy-confirmed Lewy body variant vs pure Alzheimer disease. *Arch Neurol*. 1998; 55:994-1000.
15. Salmon DP, Galasko D, Hansen LA, et al. Neuropsychological deficits associated with diffuse Lewy body disease. *Brain and Cognition*. 1996; 31:148-165.
16. Ferman TJ, Boeve BF, Silber MH, et al. Hallucinations and delusions associated with the REM Sleep behavior disorder/dementia syndrome. *The Journal of Neuropsychiatry and Clinical Neurosciences*. 1997;9:692.
17. Gnanalingham K, Byrne EJ, Thornton A, Sambrook MA, Bannister P. Motor and cognitive function in Lewy body dementia: comparison with Alzheimer's and Parkinson's diseases. *J of Neurol Neurosurg Psychiatry*. 1997; 62:243-52.
18. Gomez-Tortosa E, Newell K, Irizarry MC, Albert M, Growdon JH, Hyman BT. Clinical and quantitative pathologic correlates of dementia with Lewy bodies. *Neurology*. 1999; 53:1284-1291.
19. Ballard C, Holmes C, McKeith I et al. Psychiatric morbidity in Dementia with Lewy bodies: A prospective clinical and neuropathological comparative study with Alzheimer's disease. *Amer J. Psychiat*. 1999; 156:1039-1045.
20. Hope T, Keene J, Fairburn CG, Jacoby R, McShane R. Natural history of behavioral changes and psychiatric symptoms in Alzheimer's disease. *Brit. J. Psychiat*. 1999; 174:39-44.
21. Plazzi G, Corsini R, Provini F et al. REM sleep behavior disorders in multiple system atrophy. *Neurology*. 1997; 48:1094-1097.
22. Boeve BF, Silber MH, Ferman TJ. Association of REM Sleep Behavior Disorder and Neurodegenerative disease. *Sleep*. 1999; 22:S72.
23. Dickson DW, Schmidt ML, Lee VM-Y, Trojanowski JQ, Yen S-H. Hippocampal neurites in diffuse Lewy body disease: immunocytochemical characterization and local origin. *Acta Neuropathol*. 1994; 87:269-276.
24. Kosaka K, Yoshimura M, Ikeda K, Budka H. Diffuse type of Lewy body disease: Progressive dementia with abundant cortical Lewy bodies and senile changes of varying degree - a new disease? *Clinical Neuropathology*. 1984;3:185-192.
25. Spillantini MG, Crowther RA, Jakes R, Hasegawa M, Goedert M. Alpha-synuclein in filamentous inclusions in Lewy bodies from Parkinson's disease and dementia with Lewy bodies. *Proc Natl Acad Sci USA*. 1998; 95:6469-6473.
26. McKenzie J, Edwards RJ, Gentleman SM, Ince PG et al. A quantitative comparison of plaque types in Alzheimer's disease and senile dementia of the Lewy body type. *Acta Neuropathol*. 1996; 91:526-529.
27. Dickson D, Crystal HA, Mattiace LA, et al. Identification of normal and pathological aging in prospectively studied nondemented elderly humans. *Neurobiol Aging*. 1991; 13:179-189
28. Hansen LA, Masliah E, Galasko D, Terry RD. Plaque-only Alzheimer disease is usually the lewy body variant and vice versa. *J Neuropathol Exp Neurol*. 1993; 52:648-54.
29. Perry EK, Marshall E, Thompson P, et al. Monoaminergic activities in Lewy body dementia: relation to hallucinosis and extrapyramidal features. *J Neural Transm*. 1993; 6:167-77.
30. Perry EK, Haroutunian V, Davis KL, et al. Neocortical cholinergic activities differentiate Lewy body dementia from classical Alzheimer's disease. *Neuroreport*. 1994; 5:747-9.
31. Brizer D, Manning D. Delirium induced by poisoning with anticholinergic agents. *Am J Psychiatry*. 1982; 139:1343-4.
32. McKeith IG, Ballard CG, Harrison RWS. Neuroleptic sensitivity to risperidone in Lewy body dementia. *Lancet*. 1995; 346:699
33. Piggott MA., Perry EK, Marshall EF, et al. Nigrostriatal dopaminergic activities in dementia with Lewy bodies in relation to neuroleptic sensitivity: comparisons with Parkinson's disease. *Biol Psychiat*. 1998; 44:765-764.
34. Allen RL, Walker Z, D'Ath PJ et al. Risperidone for psychotic and behavioral symptoms in Lewy body dementia (letter). *Lancet*. 1995; 346:185.
35. Miller CH, Mohr F, Umbricht D, Woerner M, Fleischhacker WW, Lieberman JA. The prevalence of acute extrapyramidal signs and symptoms in patients treated with clozapine, risperidone and conventional antipsychotics. *J Clin Psychiatry*. 1998; 59:69-75.
36. Widman LP, Burke WJ, Pfeiffer RF, et al. Using clozapine to treat levodopa induced psychosis in Parkinson's disease: A retrospective review. *J Geriatr Psychiatry Neurol*. 1997; 10:63-66.
37. Bymaster FP, Calligaro DO, Falcone JF et al. Radioreceptor binding profile of the atypical antipsychotic olanzapine. *Neuropsychopharm*. 1996; 14:87-96.
38. Burke WJ, Pfeiffer RF, McComb RD. Neuroleptic sensitivity to Clozapine in dementia with Lewy bodies. *Journal of Neuropsychiatry and Clinical Neurosciences*. 1998; 10:227-229.
39. Kaufer DI, Catt KE, Lopez OL, DeKosky S.T. Dementia with Lewy bodies: Response of delirium-like features to donepezil. *Neurology*. 1998; 51:1512.
40. Lebert F, Pasquier F, Souliez L, Petit H. Tacrine efficacy in Lewy body dementia. *Int J Geriatr Psychiatry*. 1998;13:516-19.
41. Kaufer DI, Cummings JL, Christine D. Effect of tacrine on behavioral symptoms in Alzheimer's disease: an open-label study. *J. Geriatr Psychiatry Neurol*. 1996;9:1-6.
42. Shea C, MacKnight C, Rockwood K. Donepezil for treatment of dementia with Lewy bodies: a case series of nine patients. *International Psychogeriatrics*. 1998;10:229-238.
43. Carlson DL, Fleming KC, Smith GE, Evans JM. Management of dementia-related behavioral disturbances: A nonpharmacologic approach. *Mayo Clin Proc*. 1995; 70:1108-1115.
44. Zarit SH, Stephens MA, Townsend A., Greene R. Stress reduction for family caregivers: effects of adult day care use. *J Gerontol*. 1998; 53:S267-2677.